



Monique Gueudet-Bornstein. *Basin Street Blues II*. New Orleans 1997.

Renal cryotherapy shows promise as an option for treatment of small renal masses in select patients.

Cryosurgical Ablation of Renal Cell Carcinoma

Jason Hafron, MD, and Jihad H. Kaouk, MD

Background: Small renal masses are being commonly diagnosed incidentally in older patients. A partial nephrectomy is the first-line nephron sparing treatment option for these lesions. However, probe ablative therapy such as cryoablation is emerging as an alternative option for select patients requiring nephron sparing surgery.

Methods: The current literature regarding the management of small renal lesions with cryoablation was retrospectively reviewed. We selected six of the largest published series of renal cryoablation with a total of 320 patients. The diagnosis, staging, treatment options, mechanism, efficacy and morbidity associated with renal cryoablation were evaluated.

Results: Renal cryoablation for localized small renal masses is well tolerated and associated with a low complication rate. The range of mean tumor size in our literature review series (320 patients) was 2.3 to 2.6 cm. After a range of mean follow-up of 5.9 to 72 months, including a series with a minimum of 5 years of follow-up, the cancer specific survival was 97% to 100% and overall patient survival was 82% to 90.2%.

Conclusions: Renal cryoablation, based on available clinical reports, appears to be a curative option for patients with small localized renal cell carcinomas (RCCs) who are unwilling or unable to undergo a partial nephrectomy. With encouraging intermediate oncological follow-up available, longer-term follow-up is needed to validate the use of cryoablation as a primary treatment option.

From the Section of Laparoscopic and Robotic Surgery at the Glickman Urological Institute at the Cleveland Clinic, Cleveland, Ohio.

Submitted April 11, 2007; accepted May 5, 2007.

Address correspondence to Jihad H. Kaouk, MD, Glickman Urological Institute, Cleveland Clinic, 9500 Euclid Avenue, A100, Cleveland, OH 44195. E-mail: kaoukj@ccf.org

Dr Kaouk receives grants/research support and honorarium from Endocare, Inc. No other significant relationship exists between the authors and the companies/organizations whose products or services may be referenced in this article.

The editor of *Cancer Control*, John Horton, MB, ChB, FACP, has nothing to disclose.

Abbreviations used in this paper: RCC = renal cell carcinoma.

Introduction

In 2007 in the United States, an estimated 51,190 new cases of renal cell carcinoma (RCC) will be diagnosed and 12,890 people will die of RCC.¹ RCC represents 2% of all cancers worldwide.² For small (<4 cm) localized renal masses, partial nephrectomy provides excellent oncologic outcomes similar to those achieved with radical nephrectomy.^{3,4} However, partial nephrectomy may not be suitable for patients with increased surgical morbidity or multiple recurrent tumors. For select patients, cryoablation has emerged as an alternative surgical option with encouraging results.

The widespread use of computed tomography (CT) scans and abdominal ultrasonography has contributed to an increased incidence of RCC, mostly in patients 70 to 90 years of age.⁵ As a result, the majority of RCCs are diagnosed incidentally during investigation of unrelated complaints.^{6,7} Incidentally detected lesions typically are at a low stage with an excellent prognosis.⁸⁻¹⁰ As a result, according to the SEER (Surveillance, Epidemiology, and End Results) database over the last 18 years, renal tumor size at presentation has steadily and consistently decreased.¹¹ As tumor size has declined at the time of presentation, the methods and techniques for management of these lesions have shifted toward a nephron-sparing surgical approach and more so in urban, high-volume teaching centers.¹²

Treatment of Small Renal Masses

Observation

Depending on the specific clinical situation, observation may be a viable treatment option. It has long been known that small, incidentally discovered, well-margined renal masses are slow growing and have low metastatic potential.^{13,14} Furthermore, up to 23% of these incidentally discovered masses are benign.⁴ Women are almost twice as likely as men to have a benign lesion.¹⁵ Current radiological imaging is unable to differentiate benign from malignant renal neoplasms, and renal mass biopsy does not offer sufficient accuracy to diagnose small renal masses.¹⁶ Therefore, the natural history of small renal lesions and the likelihood of a benign lesion are the guiding principles of observation.

In a retrospective review of 29 consecutive elderly patients with contrast-enhancing renal masses smaller than 3.5 cm and suggestive of cancer, Wehle et al¹⁷ demonstrated that these lesions can be safely managed with watchful waiting and serial CT scans. During a mean follow-up period of 32 months, 4 patients underwent surgery. In 3 of these 4 patients, histological findings were consistent with RCC. There was no evidence of metastases in any of the patients. Clinical and radiological observation can be considered in a well-informed patient with significant comorbidities and a limited life expectancy.

Surgery

For lesions smaller than 4 cm, long-term oncological outcomes with nephron-sparing surgery are equivalent to those with radical nephrectomy.^{3,4} Moreover, nephron-sparing surgery results in a lower risk of renal failure,^{18,19} and health-related quality of life measures have been found to be higher in patients who have preserved renal parenchyma independent of postoperative renal function.²⁰ A recent study showed that 26% of patients with a solitary, small, renal cortical tumor (<4

cm) and two normally functioning kidneys have preexisting chronic kidney disease (glomerular filtration rate <60 mL/min), and the onset of chronic kidney disease was greater in patients who had a radical nephrectomy.²¹ As such, a partial nephrectomy is the first-line treatment option for these lesions. However, partial nephrectomy, whether open or laparoscopic, may not be the best option for all patients, especially elderly patients with significant comorbidities.

Concomitantly with the change in presentation of renal masses is a paradigm shift in the management of localized small renal lesions. Specifically, minimally invasive options such as cryoablation or procedures with limited morbidity are being investigated in patient populations in which invasive nephron-sparing surgery, whether laparoscopic or open, is not appropriate for the patient or surgeon. The potential complications of nephron-sparing kidney surgery make renal cryoablation an appealing option in high-risk surgical populations. Absolute contraindications to renal cryotherapy are patients who have a history of coagulopathy or who are receiving anticoagulation therapy and are unable to stop treatment. Cryoablation of renal lesions has been practiced for over 40 years,^{22,23} but recent advancements in cryoprobe technology have made cryoablation more applicable.

Renal Cryoablation

Renal cryoablation can be delivered using an open, laparoscopic, or percutaneous surgical approach. Following renal mass biopsy, single or multiple cryoprobes of varying diameter are placed into a renal lesion based on tumor size and shape. Cryoprobes can achieve tissue temperatures as low as -160°C within a few minutes utilizing the Joule-Thompson effect with circulating high pressure argon gas. Based on animal data, the cryoprobes are configured to develop an ice zone to freeze the renal mass with a minimum temperature of -19.4°C or lower in order for complete homogenous renal tissue necrosis.²⁴ A double freeze-thaw cycle is favored based on previous data that showed consistently larger areas of necrosis when compared to a single freeze-thaw cycle.²⁵ Also, it is necessary to extend the ice ball by a minimum of 3.1 mm beyond the edge of the tumor in order to achieve a target temperature of less than -20°C to 40°C at the tumor margin.²⁶ To ensure adequate kill temperatures at the periphery of the mass, the ice ball is extended 0.5 cm beyond the tumor edge. As such, the maximum diameter of the ice ball is at least 1 cm larger than the tumor diameter. Furthermore, the ice ball created by the cryoprobes can be monitored in real-time by ultrasound, CT, or magnetic resonance imaging (MRI) to ensure that the ice ball incorporates the intended area of treatment. The resultant cryoinjury is based on the

Table 1. — Current Series of Cryoablation

Approach	Reference	Modality of Imaging Guidance	Mean Tumor Size in cm (range)	No. of Patients	No. of Local Recurrences (%)	Cancer-Specific Survival Rate	Overall Survival Rate	Mean Follow-up (mos)
Laparoscopic	Gill et al ³⁴ and Hegarty et al ³⁵	Ultrasound	2.3 (1.0–4.5)	60	3 (6.7%)	100%	82%	72
	Cestari et al ³³	Ultrasound	2.4 (1.0–6.0)	70	1 (1.4%)	N/A	N/A	N/A
Laparoscopic/Open	Davol et al ³²	Ultrasound	2.6 (1.1–4.6)	48	5 (12.5%)	100%	89.6%	64
Percutaneous	Sewell and Shingleton ³⁸	MRI	N/A (1.1–7.5)	103	10 (10.3%)	97%	90.2%	35
	Silverman et al ³⁷	MRI	2.6 (1.0–4.6)	27	2 (7.0%)	N/A	N/A	14
	Gupta et al ³⁶	CT	2.5 (1.1–4.6)	12	15 of 16 completely ablated	N/A	N/A	5.9

size of the cryoprobe, the total freezing time, and the number of freeze-thaw cycles.

Cryobiology and Tissue Interactions

Cryoablation produces predictable cell death by a variety of mechanisms. Cellular factors include direct cellular injury, intracellular ice formation, and cellular membrane rupture. One purported mechanism involves initial freezing of the extracellular fluid compartment that in turn causes osmotic dehydration of the intracellular fluid compartment.²⁷ The shift in fluid concentration creates a high concentration of solutes within the cells that is believed to cause cellular membrane injury and damage to the enzymatic activity of the cell. In addition, the cytosol super-cools and forms intracellular ice crystals that lead to further damage of the intracellular membranes.²⁸ Damage from solute effect occurs at low cooling temperatures when the cell dehydrates, and intracellular damage occurs at high cooling temperatures when the water is trapped inside the cells.²⁶ Secondary changes from freezing involve destruction of the microcirculation²⁹ and subsequent cellular hypoxia and necrosis from vascular stasis.³⁰ Additionally, cellular apoptosis occurs throughout the renal lesion, particularly at the periphery of the renal mass.³¹

Clinical Applications of Cryoablation

Even though cryotherapy has been available for many years, it has only recently been significantly applied and critically examined. Cryoablation can be applied via a laparoscopic, percutaneous, or open surgical approach with various modalities for image guidance (Table 1).

Laparoscopic Approach

Davol et al³² reviewed their experience with 5-year clinical follow-up on 48 patients who were treated with either open or laparoscopic renal cryoablation. The

median tumor size was 2.6 cm (range 1.1 to 4.6 cm). Although the failure rate after the initial treatment was 12.5%, following retreatment the cohort achieved a cancer-free survival rate of 97.5%. The cancer-free survival rate after a single cryoablation was 87.5%, with an overall cancer-specific survival rate of 100%. This series highlights the fact that a successful cryoablation treatment might include several treatment sessions, and patients should be advised accordingly (Fig 1).

In a study from Italy, Cestari et al³³ presented the results of 70 patients who underwent laparoscopic renal cryoablation with a mean lesion diameter of 2.37 cm (range 1 to 6 cm). All procedures were performed laparoscopically except one case that was converted to open surgery. A total of 42 patients were treated transperitoneally and 28 patients were treated retroperitoneoscopically. Interval radiologic reduction in the diameter of the cryolesions was reported in all patients, and a visible renal scar appeared after 24 months. The authors concluded that their results were encouraging and further studies with longer follow-up are required to critically assess cryoablation as a form of treatment for small RCCs.

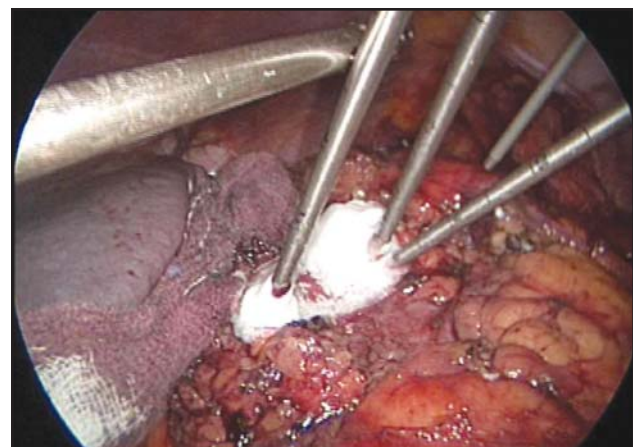


Fig 1. — Laparoscopic cryoablation of a left anterior renal lesion (background) and lateral renal lesion (foreground). One cryoprobe was used in the smaller anterior lesion while two cryoprobes were placed to ablate the entire lateral renal lesion.

Gill et al³⁴ reported the intermediate outcome (with a minimum of 3 years of follow-up) of cryoablation on 56 patients undergoing laparoscopic renal cryoablation. The mean tumor size was 2.3 cm (range 1 to 5 cm), and the mean cryolesion created was 3.6 cm. Depending on tumor location, the transperitoneal approach was used in 25% of the patients and the retroperitoneal approach in 75% of the patients. At 3 years of follow-up, 17 cryolesions (38%) had completely disappeared on follow-up MRI, and the average cryolesion size reduction was 75%. Postoperative needle biopsy found local renal tumor recurrence in 2 patients. In a recent update of this series, Hegarty et al³⁵ presented data on 60 patients with a median follow-up of 72 months and reported overall and cancer-specific 5-year survival rates of 82% and 100%, respectively. Three patients (6.7%) developed local tumor recurrence. The results of this study indicate that local recurrence rates are low and 5-year cancer specific-survival rates are excellent.

Percutaneous Approach

Percutaneous cryoablation represents the least invasive method of cryoablation. Typically, percutaneous cryotherapy is reserved for small posterior lesions that are reachable by an unimpeded tract from the skin sur-

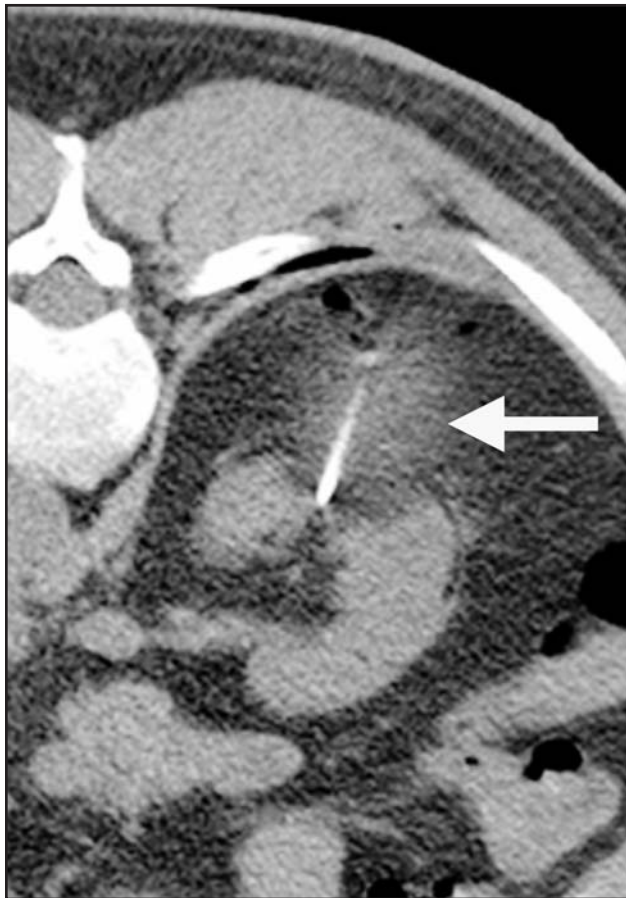

Fig 2. — Percutaneous cryoablation of a renal mass under CT guidance. Note the hypodense ice ball formed at the site of the renal mass.

face to the renal lesion. Under real-time image guidance and with the patient usually under conscious sedation, local anesthesia cryoprobes are inserted percutaneously into the renal lesion. MRI or CT scans allow the surgeon to confirm the position of the cryoprobes and monitor the ice ball in real time. Invasive MRI systems are not as readily available as CT scanners in most medical centers; however, MRI has the added benefit of decreased radiation exposure to the patient and physician.

Gupta et al³⁶ reported CT-guided percutaneous cryoablation in 27 renal tumors with a mean tumor diameter of 2.4 cm in 20 patients under conscious sedation. The procedure was successful in all patients, with each ice ball exceeding the tumor renal diameter in all three planes. Although mean imaging follow-up was short (5.9 months), 15 of the 16 cryoablated lesions showed no signs of enhancement on follow-up. The one tumor with residual enhancement occurred in a patient with a 4.6-cm tumor (Fig 2).

Using an open MRI system in 23 patients, Silverman et al³⁷ reported on 26 renal tumors with a mean diameter range of 2.6 cm (range 1 to 4.6 cm). Twenty-four out of the 26 renal tumors were successfully treated under general anesthesia. All but two tumors were completely ablated, and one other tumor required a repeat treatment. Both incomplete treatments involved the first 2 patients in the study and their lesions were 2.0 cm. The authors noted that intraprocedure CT fluoroscopy appears promising in ablating renal tumors in one session.

Sewell and Shingleton³⁸ reported their results with MRI-guided percutaneous cryoablation in 103 patients with 120 individually treated tumors. According to their results, 72 tumors were completely ablated with a single procedure, 15 patients with 18 tumors required a second cryoablation procedure, 2 patients with 4 tumors required a third cryoablation procedure, and 3 patients with 11 tumors required a fourth cryoablation procedure. Ten patients had residual disease or recurrence at the time of death (10 patients died but only 3 of the 10 deaths were disease-related). The overall patient survival rate was 90.2%, with the disease-specific survival rate being 97%. Percutaneous MRI-guided cryoablation appears to be an effective method of treatment in experienced hands. The authors reported that an exophytic location of the renal mass was the most favored location, followed by parenchymal tumors and finally lesions abutting the collecting system. Additionally, tumor diameter was an excellent predictor of success. Tumors that were <25 mm tended to be ablated successfully with a single treatment session, while tumors >40 mm typically required more than one treatment session. These are important findings when counseling patients on the likelihood of additional renal ablations.

Morbidity of Cryoablation

Surgical ablation of renal tumors appears to be a relatively safe treatment option. In a multi-institutional retrospective series of 271 ablative cases, the reported major complication rate was 1.8% with 1 death (aspiration pneumonia) that was not directly attributable to the ablation technique.³⁹ The cryoablative group of 132 cases reported two major complications: a significant hemorrhage requiring blood transfusion following percutaneous cryoablation and an open conversion due to inability to access the tumor laparoscopically. The most common complication was pain or paraesthesia at the probe insertion site. More than half of the complications in this study occurred in the first third of the procedures performed, indicating a possible learning curve associated with this new technology. Overall, an ablative procedure appears to be associated with minimal complications, and it may be a safer alternative to partial nephrectomy in patients necessitating nephron-sparing surgery but with multiple comorbidities.

Another concern with cryoablation of the kidney is when cryoinjury predisposes the kidney to further loss of renal function secondary to kidney necrosis and scarring. In a retrospective review with a mean follow-up of 20.6 months, Carvalho et al⁴⁰ reported no significant differences in preoperative and postoperative creatinine level, blood pressure, or estimated creatinine clearance. Furthermore, in the reported series of patients with solitary kidneys, serum creatinine and blood pressure were unchanged after a period of 6 months. It appears that laparoscopic renal cryoablation does not significantly affect renal function or blood pressure.

Treatment of central lesions near the collecting system raises the concern of a urine fistula. Sung et al⁴¹ demonstrated in a porcine model that in the absence of physical puncture of the collecting system with the cryoprobe, cryoinjury to the renal collecting system

heals without evidence of urinary leakage. Clinical series in which the ice ball was less than 5 mm from the collecting system did not show any evidence of urino-ma.⁴² Therefore, a central lesion treated with an ice ball that involves the renal collecting system is relatively safe based on animal and clinical data.

To our knowledge there is no prospective comparison of the perioperative outcomes between the laparoscopic and percutaneous approach to renal cryotherapy. However, when renal cryoablation is compared with open or laparoscopic partial nephrectomy, the risk of hemorrhage, urinary fistula, ureteral injury, or acute renal failure is markedly decreased. The reported complications of the different surgical approaches are compared in Table 2.

Follow-Up

Given that the renal lesions are treated in situ, a rigorous follow-up protocol is required. At our institute, follow-up MRI is performed the next day after ablation and then at 3, 6, and 12 months following the procedure and annually thereafter.⁴³ The cryolesion on follow-up CT or MRI should show no evidence of enhancement, and the ablated tumor should demonstrate stable size or a decrease in size.⁴⁴ As the technology evolves, the follow-up protocols will most likely change.

Other Ablative Modalities

The focus of this review is cryoablation of RCC, which currently has the largest and longest follow-up clinical data available. However, other ablative technologies are being evaluated clinically.

Radiofrequency ablation (RFA) has been used by many groups with promising results,^{45,46} but it has spe-

Table 2. — Morbidities Associated With Cryoablation of Renal Masses

Approach	Reference	Major Complications (no. of cases)	Minor Complications (no. of cases)	Transfusion Rate	Conversion to Open
Laparoscopic	Gill et al ³⁴ and Hegarty et al ³⁵	Splenic hematoma (1) Heart failure (1)	Pleural effusion (1) Herpetic esophagitis (1)	0%	0%
	Cestari et al ³³	Ureteropelvic junction obstruction (1) Anemia (6)	Fever (6) Gross hematuria (1) Perirenal hematoma (2) Pulmonary edema (1)	N/A	0%
Laparoscopic/Open	Davol et al ³²	None reported	Capsular fracture (4) Ileus (1)	4.1%	0%
Percutaneous	Sewell and Shingleton ³⁸	None reported	Access abscess (1) Retroperitoneal bleed (1) Gross hematuria (5%)	0.9%	0%
	Silverman et al ³⁷	Hemorrhage (1) Perirenal abscess (1)	None reported	3.7%	0%
	Gupta et al ³⁶	Hemorrhage (1)	None reported	8.3%	0%

cific disadvantages. During RFA the surgeon is unable to monitor the ablated zone effectively with the currently available technology. Also, the procedure appears not to spare the collecting system, and available follow-up is shorter for RFA than for renal cryoablation. High-intensity focused ultrasound (HIFU), used mostly in Europe and Asia, has been applied in limited studies with inconsistent results.⁴⁷ Other ablative techniques under investigation include CyberKnife (Accuray Inc, Sunnyvale, Calif),⁴⁸ a frameless, image-guided radiosurgery device that delivers high-dose radiation. Microwave therapy involves the passage of microwave energy from a flexible antennae into the tissue, resulting in coagulative necrosis,⁴⁹ and laser thermal ablation applies laser energy to ablate the tumor.⁵⁰

Future Directions

Improvements in Image Guidance

Currently, CT and MRI provide excellent visualization of the lesion. However, placement of the cryoprobes relies on the surgeon's experience and clinical judgment in proper probe localization within the renal lesion. To improve accuracy, Wacker et al⁵¹ reported an animal model in which the application of an augmented reality system was used to guide the placement of the renal needle biopsy. An augmented reality system was combined with a 1.5-T closed-bore magnetic resonance imager to navigate a biopsy needle into 50 virtual targets. The biopsy needle was placed within the intended target with a mean error of 1.1 mm ± SD 0.5.⁵¹ Navigation-guided technology may potentially improve the accuracy and placement of cryoprobes in the future, specifically in percutaneous applications.

Additionally, others have investigated robotically assisted percutaneous ablation.⁵² The combination of robotically assisted and navigation-guided technology could potentially further increase the accuracy of cryoprobe placement.

The use of contrast-enhanced ultrasonography (CEUS) to evaluate renal cryoablation has also been reported.⁵³ CEUS involves microbubble contrast agents in combination with contrast pulse sequence imaging. This technology allows the surgeon to monitor the perfusion of the ablated area in real time. However, in the United States, the use of microbubble contrast agents is currently limited clinically to cardiac imaging. Further studies are warranted to determine if there is a role for this technology in renal cryoablation.

Adjunctive Chemotherapeutics

Another area of potential improvement in the efficacy of renal cryotherapy includes adjunctive chemotherapeutics. Low-dose chemotherapy combined with cryoablation may promote freezing-induced cell death.

It is theorized that the enhanced cell death is a result of the chemotherapeutic agent initiating apoptosis prior to freezing.^{54,55} A better understanding of cryobiology and the application of chemotherapeutic agents might improve the efficacy of renal cryotherapy in the future.

Conclusions

With recent advances in imaging and probe technology, renal cryotherapy for RCC has evolved as a valid option for treatment of small renal masses in select patients. Available 5-year studies indicate that renal cryoablation is a safe and effective method for nephron-sparing treatment of small renal cancers. However, longer-term oncologic data are required before renal cryoablation can be considered as a primary treatment modality for patients with small renal masses.

References

1. Jemal A, Siegel R, Ward E, et al. Cancer statistics, 2007. *CA Cancer J Clin.* 2007;57:43-66.
2. Parkin DM, Whelan SL, Ferlay J, et al, eds. IARC Scientific Publication No. 155. *Cancer Incidence in Five Continents*. Vol. VIII. Lyon, France: International Agency for Research on Cancer; 2002.
3. Fergany AF, Hafez KS, Novick AC. Long-term results of nephron sparing surgery for localized renal cell carcinoma: 10-year followup. *J Urol.* 2000;163:442-445.
4. Lee CT, Katz J, Shi W, et al. Surgical management of renal tumors 4 cm or less in a contemporary cohort. *J Urol.* 2000;163:730-736.
5. Chow WH, Devesa SS, Warren JL, et al. Rising incidence of renal cell cancer in the United States. *JAMA.* 1999;281:1628-1631.
6. Lightfoot N, Conlon M, Kreiger N, et al. Impact of noninvasive imaging on increased incidental detection of renal cell carcinoma. *Eur Urol.* 2000;37:521-527.
7. Luciani LG, Cestari R, Tallarigo C. Incidental renal cell carcinoma-age and stage characterization and clinical implications: study of 1092 patients (1982-1997). *Urology.* 2000;56:58-62.
8. Bretheau D, Lechevallier E, Eghazarian C, et al. Prognostic significance of incidental renal cell carcinoma. *Eur Urol.* 1995;27:319-323.
9. Jayson M, Sanders H. Increased incidence of serendipitously discovered renal cell carcinoma. *Urology.* 1998;51:203-205.
10. Homma Y, Kawabe K, Kitamura T, et al. Increased incidental detection and reduced mortality in renal cancer: recent retrospective analysis at eight institutions. *Int J Urol.* 1995;2:77-80.
11. Nguyen MM, Gill IS, Ellison LM. The evolving presentation of renal carcinoma in the United States: trends from the Surveillance, Epidemiology and End Results program. *J Urol.* 2006;176(6 pt 1):2397-2400.
12. Hollenbeck BK, Taub DA, Miller DC, et al. National utilization trends of partial nephrectomy for renal cell carcinoma: a case of underutilization? *Urology.* 2006;67:254-259. Epub 2006 Jan 25.
13. Bosniak MA. The small (less than or equal to 3.0 cm) renal parenchymal tumor: detection, diagnosis, and controversies. *Radiology.* 1991;179:307-317.
14. Bosniak MA, Birnbaum BA, Krinsky GA, et al. Small renal parenchymal neoplasms: further observations on growth. *Radiology.* 1995;197:589-597.
15. Snyder ME, Bach A, Kattan MW, et al. Incidence of benign lesions for clinically localized renal masses smaller than 7 cm in radiological diameter: influence of sex. *J Urol.* 2006;176(6 pt 1):2391-2395.
16. Campbell SC, Novick AC, Herts B, et al. Prospective evaluation of fine needle aspiration of small, solid renal masses: accuracy and morbidity. *Urology.* 1997;50:25-29.
17. Wehle MJ, Thiel DD, Petrou SP, et al. Conservative management of incidental contrast-enhancing renal masses as safe alternative to invasive therapy. *Urology.* 2004;64:49-52.
18. McKiernan J, Simmons R, Katz J, et al. Natural history of chronic renal insufficiency after partial and radical nephrectomy. *Urology.* 2002;59:816-820.
19. Lau WK, Blute ML, Weaver AL, et al. Matched comparison of radical nephrectomy vs nephron-sparing surgery in patients with unilateral renal cell carcinoma and a normal contralateral kidney. *Mayo Clin Proc.* 2000;75:1236-1242.
20. Clark PE, Schover LR, Uzzo RG, et al. Quality of life and psycho-

logical adaptation after surgical treatment for localized renal cell carcinoma: impact of the amount of remaining renal tissue. *Urology*. 2001;57:252-256.

21. Huang WC, Levey AS, Serio AM, et al. Chronic kidney disease after nephrectomy in patients with renal cortical tumours: a retrospective cohort study. *Lancet Oncol*. 2006;7:735-740.

22. Lutzeyer W. Advancements in operative therapy (urology). *Langenbecks Arch Chir*. 1972;332:137-145.

23. Lutzeyer W, Lymberopoulos S, Breining H, et al. Experimental cryosurgery of the kidney. *Langenbecks Arch Chir*. 1968;322:843-847.

24. Chosy SG, Nakada SY, Lee FT Jr, et al. Monitoring renal cryosurgery: predictors of tissue necrosis in swine. *J Urol*. 1998;159:1370-1374.

25. Woolley ML, Schulsinger DA, Durand DB, et al. Effect of freezing parameters (freeze cycle and thaw process) on tissue destruction following renal cryoablation. *J Endourol*. 2002;16:519-522.

26. Campbell SC, Krishnamurthi V, Chow G, et al. Renal cryosurgery: experimental evaluation of treatment parameters. *Urology*. 1998;52:29-34.

27. Mazur P. Freezing of living cells: mechanisms and implications. *Am J Physiol*. 1984;247(3 pt 1):C125-C142.

28. Hoffmann NE, Bischof JC. The cryobiology of cryosurgical injury. *Urology*. 2002;60:40-49.

29. Daum PS, Bowers WD Jr, Tejada J, et al. Vascular casts demonstrate microcirculatory insufficiency in acute frostbite. *Cryobiology*. 1987;24:65-73.

30. Hoffmann NE and Bischof JC. Cryosurgery of normal and tumor tissue in the dorsal skin flap chamber. Part II: injury response. *J Biomech Eng*. 2001;123:310-316.

31. Baust JG, Gage AA, Clarke D, et al. Cryosurgery: a putative approach to molecular-based optimization. *Cryobiology*. 2004;48:190-204.

32. Davol PE, Fulmer BR, Rukstalis DB. Long-term results of cryoablation for renal cancer and complex renal masses. *Urology*. 2006;68(1 suppl):S2-6.

33. Cestari A, Guazzoni G, Naspro R, et al. Laparoscopic renal cryoablation (LRC) of small renal masses: lesson learned after 70 procedures. *Eur Urol Suppl*. 2006;5:220.

34. Gill IS, Remer EM, Hasan WA, et al. Renal cryoablation outcome at 3 years. *J Urol*. 2005;173:1903-1907.

35. Hegarty NJ, Gill IS, Spaliviero M, et al. Renal cryoablation: 5 year outcomes. *J Urol*. 2006;175(suppl):351. Abstract 1091.

36. Gupta A, Allaf ME, Kavoussi LR, et al. Computerized tomography guided percutaneous renal cryoablation with the patient under conscious sedation: initial clinical experience. *J Urol*. 2006;175:447-453.

37. Silverman SG, Tuncali K, vanSonnenberg E, et al. Renal tumors: MR imaging-guided percutaneous cryotherapy: initial experience in 23 patients. *Radiology*. 2005;236:716-724.

38. Sewell P, Shingleton W. Five-year treatment success and survival of patients treated with percutaneous IMRI guided and monitored renal cell carcinoma cryoablation. *BJU Int*. 2004;94:106. Abstract MP-1609.

39. Johnson DB, Solomon SB, Su LM, et al. Defining the complications of cryoablation and radio frequency ablation of small renal tumors: a multi-institutional review. *J Urol*. 2004;172:874-877.

40. Carvalhal EF, Gill IS, Meraney AM, et al. Laparoscopic renal cryoablation: impact on renal function and blood pressure. *Urology*. 2001;58:357-361.

41. Sung GT, Gill IS, Hsu TH, et al. Effect of intentional cryo-injury to the renal collecting system. *J Urol*. 2003;170:619-622.

42. Warlick CA, Lima GC, Allaf ME, et al. Clinical sequelae of radiographic ice ball involvement of collecting system during computed tomography-guided percutaneous renal tumor cryoablation. *Urology*. 2006;67:918-922.

43. Remer EM, Weinberg EJ, Oto A, et al. MR imaging of the kidneys after laparoscopic cryoablation. *AJR Am J Roentgenol*. 2000;174:635-640.

44. Anderson JK, Shingleton WB, Cadeddu JA. Imaging associated with percutaneous and intraoperative management of renal tumors. *Urol Clin North Am*. 2006;33:339-352.

45. Gervais DA, McGovern FJ, Arellano RS, et al. Radiofrequency ablation of renal cell carcinoma: Part 1. Indications, results, and role in patient management over a 6-year period and ablation of 100 tumors. *AJR Am J Roentgenol*. 2005;185:64-71.

46. Varkarakis IM, Allaf ME, Inagaki T, et al. Percutaneous radio frequency ablation of renal masses: results at a 2-year mean followup. *J Urol*. 2005;174:456-460.

47. Deane LA, Clayman RV. Review of minimally invasive renal therapies: needle-based and extracorporeal. *Urology*. 2006;68(1 suppl):26-37.

48. Ponsky LE, Crownover RL, Rosen MJ, et al. Initial evaluation of cyberknife technology for extracorporeal renal tissue ablation. *Urology*. 2003;61:498-501.

49. Ankem MK, Nakada SY. Needle-ablative nephron-sparing surgery. *BJU Int*. 2005;95(2 suppl):46-51.

50. de Jode MG, Vale JA, Gedroyc WM. MR-guided laser thermoablation of inoperable renal tumors in an open-configuration interventional MR scanner: preliminary clinical experience in 3 cases. *J Magn Reson Imaging*. 1999;10:545-549.

51. Wacker FK, Vogt S, Khamene A, et al. An augmented reality system for MR image-guided needle biopsy: initial results in a swine model. *Radiology*. 2006;238:497-504.

52. Solomon SB, Patriciu A, Bohlman ME, et al. Robotically driven interventions: a method of using CT fluoroscopy without radiation exposure to the physician. *Radiology*. 2002;225:277-282.

53. Wink MH, Lagerveld BW, Laguna MP, et al. Cryotherapy for renal-cell cancer: diagnosis, treatment, and contrast-enhanced ultrasonography for follow-up. *J Endourol*. 2006;20:456-459.

54. Clarke DM, Hollister WR, Baust JG, et al. Cryosurgical modeling: sequence of freezing and cytotoxic agent application affects cell death. *Mol Urol*. 1999;3:25-31.

55. Clarke DM, Baust JM, Van Buskirk RG, et al. Chemo-cryo combination therapy: an adjunctive model for the treatment of prostate cancer. *Cryobiology*. 2001;42:274-285.